



## PHOTO CLINIC

# Rhabdomyosarcoma of the Lower Eye Fornix and Conjunctiva in a Child

Samin Alavi

Pediatric Congenital Hematologic Disorders Research Center, Shahid Beheshti University of Medical Sciences, Tehran, Iran

## ARTICLE INFO

### Article History:

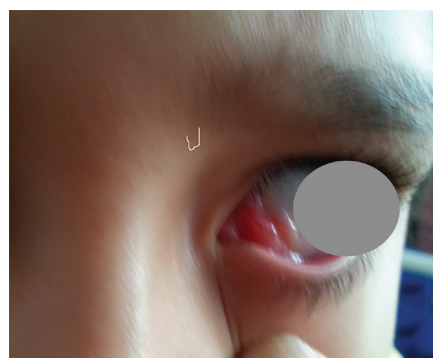
Received: 12.01.2017

Accepted: 01.03.2017

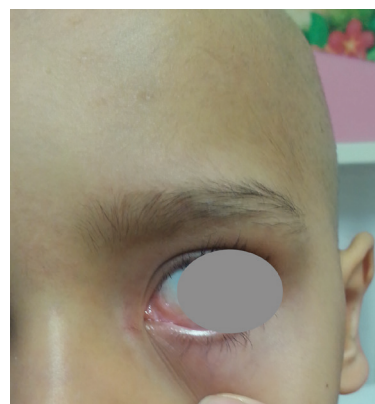Please cite this article as: Alavi S. Rhabdomyosarcoma of the Lower Eye Fornix and Conjunctiva in a Child. IJBC 2017; 9(2): 67-68.

A 6-year-old boy was presented with a small polypoid growth in inner conjunctival fornix of the left eye. The parents noted first the lesion as conjunctival congestion associated with dilated episcleral vessels three weeks ago. He received a trial of topical corticosteroid which was not helpful. Examination of the eye described a papillomatous fleshy tissue arising from the caruncle, extending onto bulbar conjunctivae, occupying about three clock hours (figure 1). A conjunctival punch biopsy was approached under general anesthesia which was compatible with embryonal rhabdomyosarcoma (RMS). Immunohistochemical analysis was positive for desmin and myoglobin. Orbital MRI scan showed an enhanced thickening of the lower part of the conjunctiva without orbital infiltration. Extensive staging work-up was negative. According to Intergroup RMS study classification, he was considered as stage III and was treated with chemotherapy alone. One month after chemotherapy eye examination was almost normal (figure 2). The child is in complete remission after 4 years.

RMS is the most common soft-tissue sarcoma of the head and neck in childhood and contains 4% of pediatric malignancies, with 10% of all cases arising in the orbit. Most ocular RMS arise in the soft tissues of the orbit but seldom can occur in other ocular adnexal structures and even within the eye.<sup>1</sup> Orbital RMS is usually extraconal (37–87%) or both intra- and extraconal (13–47%) and more commonly superonasal in location especially for embryonal RMS (inferior location is more common for



**Figure 1:** Tumoral mass in the lower eyelid at forniceal conjunctive at diagnosis.



**Figure 2:** RMS after chemotherapy shows regression of the tumoral mass.

alveolar).<sup>2</sup> It may present with misleading signs such as alterations of the eyelid, conjunctiva or even caruncle,<sup>3</sup> the same as our case.

Orbital RMS has a favorable prognosis because of its anatomic site, (symptoms become apparent at an early stage), favorable histology, the histologic subtype (80% embryonal) and also the age of the patient.<sup>1</sup> Overall survival is excellent for groups I, II and III (92% at 5 years and 87% at 10 years).<sup>4</sup>

**Conflict of Interest:** None declared.

## References

1. Shields JA, Shields CL. Rhabdomyosarcoma: review for the ophthalmologist. *Surv Ophthalmol.* 2003;48(1):39-57. PubMed PMID: 12559326.
2. Conneely MF, Mafee MF. Orbital rhabdomyosarcoma and simulating lesions. *Neuroimaging Clin N Am.* 2005;15(1):121-36. doi: 10.1016/j.nic.2005.02.006. PubMed PMID: 15927864.
3. Freling NJ, Merks JH, Saeed P, Balm AJ, Bras J, Pieters BR, et al. Imaging findings in craniofacial childhood rhabdomyosarcoma. *Pediatr Radiol.* 2010;40(11):1723-38; doi: 10.1007/s00247-010-1787-3. PubMed PMID: 20725831. PubMed Central PMCID: PMC2950273.
4. Jurdy L, Merks JH, Pieters BR, Mourits MP, Kloos RJ, Strackee SD, et al. Orbital rhabdomyosarcomas: A review. *Saudi J Ophthalmol.* 2013; 27(3):167-75. doi: 10.1016/j.sjopt.2013.06.004. PubMed PMID: 24227982. PubMed Central PMCID: PMC3770217.