



CASE REPORT

Extramedullary Hematopoiesis in a Patient with Transfusion Dependent Beta-Thalassemia Presenting with Cord Compression

Mehran Karimi^{1*}, Tahereh Zarei¹, Parisa Pishdad²

¹Hematology Research Center, Shiraz University of Medical Sciences, Shiraz, Iran

²Medical Imaging Research Center, Shiraz University of Medical Sciences, Shiraz, Iran

ARTICLE INFO

Article History:

Received: 25.08.2017

Accepted: 03.11.2017

Keywords:

Extramedullary hematopoiesis

Beta-thalassemia major

Hydroxyurea

Radiotherapy

Blood transfusion

*Corresponding author:

Mehran Karimi,
Professor of Pediatrics Hematology &
Oncology,
Hematology Research Center,
Shiraz University of Medical Sciences,
Shiraz, Iran
Tel\Fax: +98 71 36122263
Email: mkarimi820@gmail.com

ABSTRACT

Extramedullary hematopoiesis (EMH) is a physiological compensatory phenomenon occurring in many hemolytic anemias including thalassemia. Besides transfusion, radiotherapy, surgery or a combination of these modalities, hydroxyurea (HU) as an optimal treatment has been described occasionally. We described a case of beta-thalassemia major who has been on regular blood transfusion and developed EMH that was treated with HU combined with radiotherapy.

EMH should also be considered in thalassemia major patients, although it is more common in non-transfusion dependent thalassemia patients. HU combined with low dose radiotherapy along with regular blood transfusion are suggested as good treatment options for patients with EMH.

Please cite this article as: Karimi M, Zarei T, Pishdad P. Extramedullary Hematopoiesis in a Patient with Transfusion Dependent Beta-Thalassemia Presenting with Cord Compression. IJBC 2018; 10(1): 28-30.

Introduction

Extramedullary hematopoiesis (EMH) is a compensatory phenomenon occurring because of insufficient bone marrow function that can produce ectopic hematopoietic elements outside of the bone marrow and peripheral blood.¹ It occurs in patients with hemolytic anemia, especially in non-transfusion dependent thalassemia and less common in thalassemia major patients, however it is also present in other hematological diseases such as myelofibrosis, polycythemia vera, leukemia, lymphoma and sickle cell anemia.^{1,2}

Extramedullary hematopoiesis (EMH) as a tumor-like mass usually manifests in the spleen and liver and occasionally in lymph nodes. It may also occur in uncommon locations such as the skin, heart, lungs, thymus, breast, central nervous system, middle ear and paratracheal region.³

Diagnosis and management of EMH is important for prevention of cord compression and permanent neurological deficits and decreasing the incidence of irreversible neurologic damage in paraspinal locations. Magnetic resonance imaging (MRI), computed tomography scanning, and ultrasonography are diagnostic methods for diagnosis of EMH.⁴

Management options include repeated blood transfusions to down regulate erythropoietin production, surgical decompression and radiotherapy to halt the production of overgrown marrow tissue alone or in combination with blood transfusion. Recently, cytostatic agents such as hydroxyurea (HU) and erythropoietin were also described, however; the optimal management of such patients remains controversial.⁵

Herein, we describe a case of transfusion dependent beta-thalassemia major presenting with cord compression

due to EMH that was treated by HU combined with radiotherapy.

Case Report

A 28-year-old man (weight 69 kg and height 173 cm) on regular blood transfusion was referred to thalassemia clinic with severe back pain, paresthesia, weakness of lower extremities and inability in walking which started since 10 months ago. It was gradually increased over this period. He was diagnosed as beta thalassemia major by CBC and hemoglobin electrophoresis at the age of 6 months. He also had been receiving subcutaneous deferoxamine by pump infusion as iron chelating agent since the age of three years old. Deferasirox as oral iron chelating agent (20-25 mg/kg/once per day) was substituted for deferoxamine due to poor compliance. All clinical and hematological data are summarized in Table 1. On physical examination, spleen was palpable 3 cm below costal margin.

T1-weighted MRI of the thoracic spine with and without contrast was performed which showed extensive paraspinal and extradural intraspinal masses representing EMH (Figure 1). The patient was scheduled to receive HU

1500 mg/day (22mg/kg) along with blood transfusion as well as ten fractions (200 Gy per fraction) of low dose radiotherapy. His back pain, leg paresthesia and difficulty in walking improved after one month of therapy and EMH masses disappeared after 6 months of treatment with hydroxyurea (Figure 2).

The patient is now on HU (15 mg/kg/day) and deferasirox without any complication during nine months of follow-up after complete remission. Informed consent was signed by the patient.

Discussion

EMH can occur in patients with hemoglobinopathies including sickle cell disease, thalassemia and myelofibrosis, but it is particularly common in thalassemia intermedia patients.⁶ EMH is almost exclusively asymptomatic and is believed that more than 80% of cases may remain asymptomatic, but in rare cases due to spinal cord compression it leads to a variety of neurological symptoms.⁵ The first description of spinal cord compression due to EMH in thalassemia was reported by Gatto in 1954. The diagnosis at that time was based on clinical examination and myelography.⁷

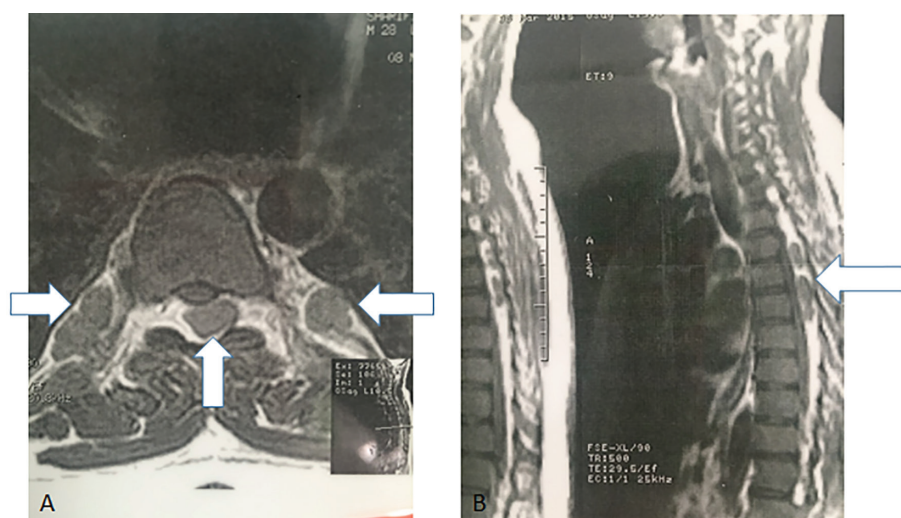


Figure 1: Axial and sagittal T1-weighted MR imaging before treatment with hydroxyurea. Extensive paraspinal and extradural intraspinal masses representing extra medullary hematopoiesis.

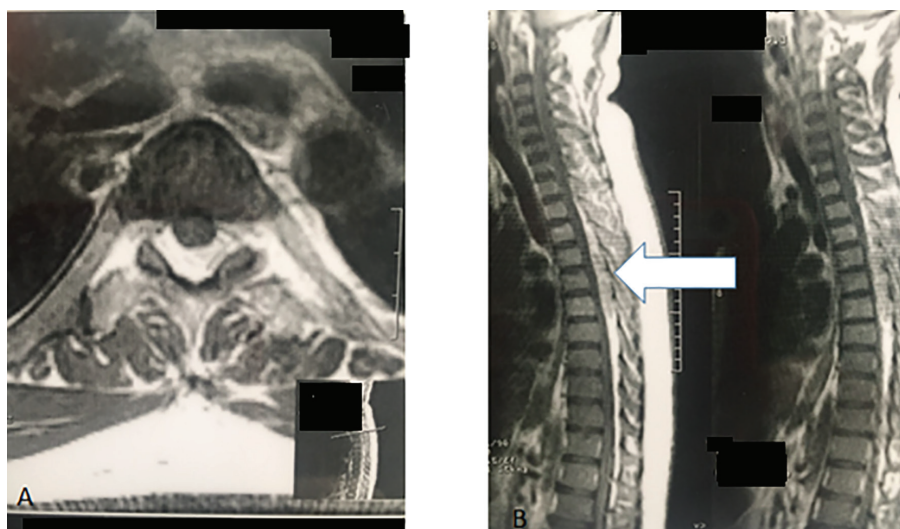


Figure 2: Axial and sagittal T1-weighted MR imaging after treatment with hydroxyurea. Significant improvement evidenced by absence of intraspinal masses of extramedullary hematopoiesis.

At present, MRI appears to be the modality of choice for evaluation of spinal cord compression. After that report, many other cases of EMH at different sites have been reported in the literature but their management still remains controversial.⁸

There are several studies that shows EMH is more common in non-transfusion-dependent thalassemia patients (Thalassemia Intermedia), in which the incidence of EMH in these patients may reach up to 20%, while in transfusion-dependent thalassemia major patients the incidence remains <1% due to regular blood transfusion.^{9,10}

Our patient was a case of thalassemia major who was presented with signs and symptoms suggestive of EMH. We considered higher doses of hydroxyurea (22 mg/kg/day) along with radiotherapy for the patient with good clinical response.¹¹

The patient tolerated well HU and low dose radiotherapy with no evidence of recurrence until 9 months after remission.

The pre-transfusion hemoglobin levels of 8.5-9 gr/dl might be tolerated well in adult patients,¹² but this case conveyed that it should be individualized since this threshold may not suppress the bone marrow adequately and hence results in EMH. It seems that one may suggest that pre-transfusion hemoglobin levels be maintained above 10 gr/dl to prevent development of EMH in thalassemia major patients.

Conclusion

In patients with thalassemia, paraspinal EMH may cause spinal cord compression. Therefore, rapid diagnosis and treatment is important to prevent irreversible damage to the spinal cord and improve functional outcome. EMH should be considered as a differential diagnosis in patients with chronic hemolytic anemia presenting with spinal cord symptoms, although it is not common in patients with beta-thalassemia major.

Acknowledgement

We thank Sheryl Nikpoor for editing and improving the language of the manuscript.

Conflict of Interest: None declared.

References

- Karimi M, Cohan N, Bagheri MH, Lotfi M, Omidvari S, Geramizadeh B. A lump on the head. *The Lancet*. 2008;372(9647):1436. doi: 10.1016/S0140-6736(08)61590-1. PubMed PMID:18940467.
- Hassanzadeh M. Extramedullary Hematopoiesis in Thalassemia. *N Engl J Med*. 2013;369(13):1252. doi: 10.1056/NEJMicm1303084. PubMed PMID: 24066746.
- Al-Aabassi A, Murad B. Presacral extramedullary hematopoiesis: a diagnostic confusion concerning a rare presentation. *Med Princ Pract*. 2005;14(5):358-62. doi: https://doi.org/10.1159/000086936. PubMed PMID: 16103704.
- Zhu G, Wu X, Zhang X, Wu M, Zeng Q, Li X. Clinical and imaging findings in thalassemia patients with extramedullary hematopoiesis. *Clin Imaging*. 2012;36(5):475-82. doi: https://doi.org/10.1016/j.clinimag.2011.11.019. PubMed PMID: 22920349.
- Haidar R, Mhaidli H, Taher AT. Paraspinal extramedullary hematopoiesis in patients with thalassemia intermedia. *Eur Spine J*. 2010;19(6):871-8. doi: 10.1007/s00586-010-1357-2. PubMed PMID: 20204423. PubMed Central PMCID: PMC2899982.
- Chute DJ, Fowler DR. Fatal hemothorax due to rupture of an intrathoracic extramedullary hematopoietic nodule. *Am J Forensic Med Pathol*. 2004;25(1):74-7. PubMed PMID: 15075694.
- Gatto I, Terrana V, Biondi L. [Compression of the spinal cord due to proliferation of bone marrow in epidural space in a splenectomized person with Cooley's disease]. *Haematologica*. 1953;38(1):61-76. PubMed PMID: 13151530.
- Salehi S, Koski T, Ondra S. Spinal cord compression in beta-thalassemia: case report and review of the literature. *Spinal Cord*. 2004;42(2):117-23. doi: 10.1038/sj.sc.3101544. PubMed PMID: 14765145.
- Taher A, Isma'eel H, Cappellini MD. Thalassemia intermedia: revisited. *Blood Cells Mol Dis*. 2006;37(1):12-20. doi: 10.1016/j.bcmd.2006.04.005. PubMed PMID: 16737833.
- Prabhakar S, Chopra J, Khosla V, Dash S, Banerjee A. Spinal cord compression in homozygous beta thalassaemia. *Surg Neurol*. 1980;13(5):351-4. PubMed PMID: 7385000.
- Karimi M, Cohan N, Pishdad P. Hydroxyurea as a first-line treatment of extramedullary hematopoiesis in patients with beta thalassemia: Four case reports. *Hematology*. 2015;20(1):53-7. doi.org/10.1179/1607845414Y.00000000168. PubMed PMID: 24717020.
- Cappellini M-D, Cohen A, Porter J, Taher A, Viprakasit V, editors. Guidelines for the management of Transfusion Dependent Thalassaemia (TDT) [Internet]. 3rd edition. Nicosia (CY): Thalassaemia International Federation; 2014.