



## PHOTO CLINIC

## Pulmonary Capillary Leak Syndrome

Rakul Nambiar, Anoop T.M\*, Harish Sugathan

*Department of Medical Oncology, Regional Cancer Centre, Thiruvananthapuram*

### ARTICLE INFO

#### Article History:

Received: 12.08.2017

Accepted: 01.10.2017

#### \*Corresponding author:

Anoop T.M, MD, DM, DNB;  
Assistant Professor, Department of  
Medical Oncology, Regional Cancer  
Centre, Thiruvananthapuram  
Email: [dranooptm@yahoo.co.in](mailto:dranooptm@yahoo.co.in)

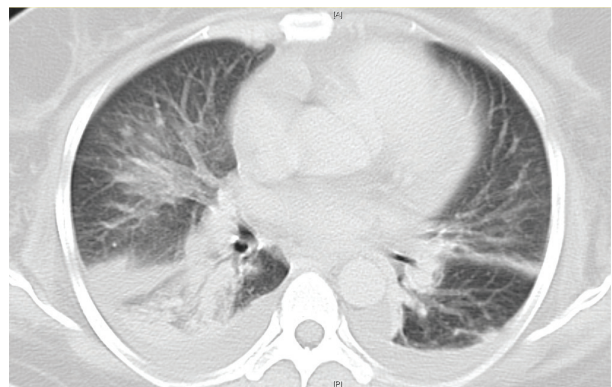
Please cite this article as: Nambiar R, TM A, Sugathan H. Pulmonary Capillary Leak Syndrome. IJBC 2017; 10(1): 33-34.

We report a rare case of capillary leak syndrome who presented with features characteristic of increased capillary permeability restricted to the lungs.

A 57-year-old woman with metastatic breast cancer was on docetaxel as palliative therapy. She used to receive premedication with dexamethasone for 12 hours prior to starting chemotherapy. After receiving the third dose of docetaxel (cumulative dose of 300 mg/m<sup>2</sup>), she developed shortness of breath and pink frothy sputum within 6 hours. On physical examination, she was dyspneic and had peripheral cyanosis with an arterial oxygen saturation of 84%. Blood pressure was 164/100 mm Hg and heart rate was 120 beats /min. Jugular venous pressure was not elevated. Minimal edema over the legs was evident. Blood and sputum cultures were negative. Respiratory sounds were significant for bilateral diffuse crepitations. CT-scan of the chest demonstrated bilateral moderate pleural effusion and consolidation in both lower lobes. Echocardiography did not reveal any features of cardiac failure suggesting a diagnosis of non-cardiogenic pulmonary edema. She was managed on non-invasive pressure support ventilation, diuretics and bronchodilators. She improved with supportive measures and clinical manifestations completely disappeared within 48 hours after admission.

Capillary leak syndrome, secondary to docetaxel therapy manifests with peripheral generalized edema, pleural and pericardial effusion and ascites. This syndrome is associated with cumulative doses of docetaxel and can be effectively prevented by glucocorticoid premedication. Pulmonary capillary leak syndrome has been reported previously where the peripheral signs are less compared

to the lung manifestations.<sup>1,2</sup> The pathophysiology of pulmonary edema in our patient was also probably due to acute capillary leak syndrome due to docetaxel. The unusual features in our case were the occurrence of capillary leak syndrome at a lesser cumulative dose of docetaxel where it usually manifests following higher doses (around doses of 480 mg/m<sup>2</sup>)<sup>3</sup> and the features being restricted predominantly to the lungs. This case also highlights the fact that capillary leak syndrome may occur with docetaxel administration even with premedication.<sup>3</sup> The main differential diagnosis for dyspnea following docetaxel infusion would be taxane-induced interstitial pneumonitis which is usually manifested as acute diffuse interstitial pneumonia, subacute diffuse interstitial pneumonitis, pulmonary opacities with peripheral eosinophilia and pulmonary fibrosis. Imaging can be



**Figure 1:** Computed tomography scan of the chest showed bilateral moderate pleural effusion and consolidation in both lower lobes.

helpful in differentiating interstitial pneumonitis from capillary leak syndrome because the former is usually associated with an increase in reticular markings with or without ground glass opacities (figure 1).

**Conflict of Interest:** None declared.

## References

1. Amathieu R, Tual L, Fessenmeyer C, Dhonneur G. [Docetaxel-induced acute pulmonary capillary-leak syndrome mimicking cardiogenic oedema]. *Ann Fr Anesth Reanim.* 2007; 26(2):180-1. doi: 10.1016/j.annfar.2006.10.024. PubMed PMID: 17169525.
2. Read WL, Mortimer JE, Picus J. Severe interstitial pneumonitis associated with docetaxel administration. *Cancer.* 2002; 94(3):847-53. PubMed PMID: 11857321.
3. Hosonaga M, Ito Y, Tokudome N, Takahashi S, Iwase T, Hatake K. A lower dose of docetaxel at 60 mg/m<sup>2</sup> could be continued longer for controlling peripheral edema in patients with metastatic breast cancer. *Breast Cancer.* 2012; 19(4): 329-34.. doi:10.1007/s12282-011-0297-y.